

Original Research Article

Occult phacomorphic glaucoma - a new clinical entity

Vasile Potop^{1,2}, Cristina Nicula^{3,4} and Dana Dascalescu²

Abstract

¹Clinical Hospital of Ophthalmologic Emergencies, Piata Alexandru Lahovari 1, Bucharest, Romania

²"Carol Davila" University of Medicine and Pharmacy, Bulenardul Eroii Sanitari 8, 050474 Bucharest, Romania

³Clinical Emergency Hospital Cluj-Napoca, Clinicilor Street 3-5, 400006, Cluj-napoca, Romania

⁴"Iuliu Hateganu" University of Medicine and Pharmacy, Victor Babes Street 8, 400012 Cluj-Napoca, Romania

*Corresponding Author's E-mail: danadascalescu@yahoo.com

Phacomorphic glaucoma is known as a secondary angle closure glaucoma caused by special forms of advanced cataract, usually associated with an increase in lens volume, called intumescent cataract. We present a series of 11 cases that associated increased sagittal diameter in a transparent lens, which induced the condition. A clear lens in a relatively young patient (fourth-fifth decade of life) can obscure its involvement in the disease mechanism. Patients presented after a poor response to peripheral laser iridotomy with high intraocular pressure (IOP), glaucomatous optic neuropathy, a clear lens and mild refractive changes. All patients were investigated thoroughly including biometry and ultrabiomicroscopy (UBM) with anterior chamber depth and lens measurements. After establishing the importance of the lens in the pathogenesis of this disease we performed phacoemulsification with a positive outcome in all cases, confirming once again our theory. We considered this new entity occult phacomorphic glaucoma in order to differentiate it from the one associated to advanced cataract and to highlight the fact that there are no lens induced myopia or transparence changes. Lens involvement is obscured by its transparency and can be documented by UBM.

Key words: Secondary angle closure glaucoma, Phacomorphic glaucoma, Occult phacomorphic glaucoma, Phacoemulsification in glaucoma

INTRODUCTION

In 2013 about 20 million people were diagnosed with primary angle closure glaucoma and out of them, more than 4 million presented a severe risk of bilateral blindness (Tham et al. 2014; Douglas et al., 1975). The number people with angle closure glaucoma is expected to rise up to 23 million by 2020 and up to 32 million by 2040 (Tham et al. 2014; Douglas et al., 1975). Although the prevalence for angle closure glaucoma is lower than the one for open angle glaucoma, these patients have a higher risk for vision loss because they usually present with more advanced optic neuropathy and have a faster rate of progression (Douglas et al., 1975; Dhillon et al., 1990; Rosman et al., 2002; Lee et al. 2004).

Despite the fact that a narrow angle doesn't necessary have the tendency to closure, there are some anatomical aspects that predispose to angle closure: shallow anterior chamber, large ciliary body, large iris,

eyes with short sagittal diameter or high sympathetic tone that determines a hypertrophic pupillary dilator (Yip et al, 2007; Wang et al, 2011; Tarongoy et al, 2009).

Studies that present the importance of the lens in the pathophysiology of angle closure glaucoma have been presented for many years (Lowe et al, 1969; Heys et al, 1999). The mechanisms by which it could determine angle closure include increased lens volume (approximately 30% of the cases) and anterior positioned lens (about 60% of the cases) (Heys et al, 1999). More recent studies have revealed that lens vault and thickness provide a better understanding of the angle closure than the lens sagittal diameter or position (Nongpiur et al., 2011). Also, Aung et al conducted a study on the congener eye in patients with acute angle closure and determined that the most important factor in the angle closure is represented by the configuration of

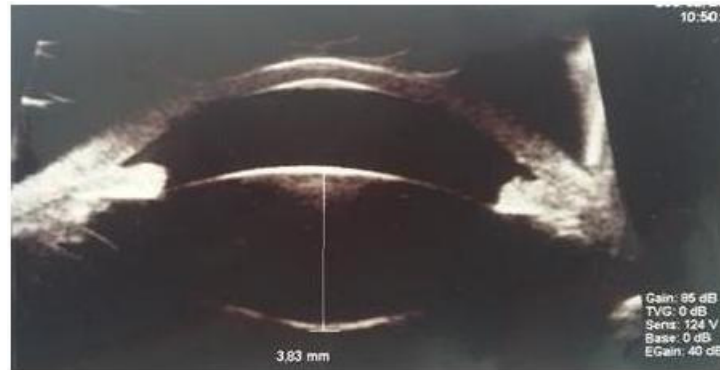


Figure 1. UBM showing increased sagittal lens volume and shallow anterior chamber prior to the surgery and postoperative aspect

the lens (Aung et al., 2004).

Other studies present the effect of lens extraction in angle closure glaucoma and reveal that this method is accompanied by a consistent and stable lowering of the intraocular pressure (Lam et al. 2007; Vizzeri et al 2010; Tham et al 2009; Reay et al 2015). Although the preoperative levels also play a role in the final IOP, the most important factor influencing the outcome remains the lens (Lam et al. 2007; Vizzeri et al 2010; Tham et al 2009; Reay et al 2015).

This type of angle closure glaucoma does not associate lens induced myopia or transparency changes but it implies that this is a lens induced entity so we considered it occult phacomorphic glaucoma (Heys et al, 1999).

METHODS

We present a series of 11 cases of angle closure glaucoma in adults in the 4th decade of life that presented with high IOP and glaucomatous optic neuropathy. All patients were conventionally treated without success prior to the current presentation and had related complications. We decided to investigate further these cases and after performing an UBM we found that all patients had an increased sagittal diameter of the lens. In order to apply a stable treatment we performed phacoemulsification with an intraocular lens implantation. The surgery was successful, visual acuity remaining stable or improving and IOP being lower and stable.

Out of the 11 cases we present the 3 most representative ones.

First case is of a 41 year old female patient that presented to the Emergency Room for severe eye pain in her left eye. Patient history revealed RE acute angle closure 2 years before, after which peripheral laser iridotomy and then trabeculectomy were performed and LE peripheral laser iridotomy. Her RE presented a BCVA of 0,3 Snellen, an IOP of 30mmHg with prostaglandin

analogue fixed combination beta-blocker and carbonic anhydrase inhibitor and a C/D ratio of 0,9. Her LE presented a BCVA of 1 Snellen, an IOP of 42mmHg with prostaglandin analogue fixed combination beta-blocker and carbonic anhydrase inhibitor and a C/D ratio of 0,9. UBM showed OU increased sagittal lens volume (3,83mm) and shallow anterior chamber (Figure 1). After the IOP was lowered with systemic carbonic anhydrase inhibitor and hyperosmotic agents we performed phacoemulsification with IOL implantation (+31D). Postoperative evolution included temporal choroid detachment that resolved spontaneously. 3 weeks later phacoemulsification with IOL implantation (+32D) was performed in her LE also with a positive outcome. 1 year later visual acuity was 0,3 and 1 Snellen respectively. The IOP remained stable at 16mmHg and 19 mmHg respectively with the same treatment used prior to the surgery.

Another case is of a 46 year old hyperopic female patient that presented for severe eye pain in her LE. Patient history revealed OU peripheral laser iridotomy. BCVA OU was 1 Snellen and IOP was 15mmHg with fixed combination beta-blocker and carbonic anhydrase inhibitor in her LE and 48mmHg with prostaglandin analogue fixed combination beta-blocker and carbonic anhydrase inhibitor in her RE. C/D ratios were 0,3 and 0,6 respectively. UBM also showed shallow anterior chamber (Figure 2) and increased sagittal lens volume (4,72 mm) (Figure 3). We started intensive hypotensive treatment with systemic carbonic anhydrase inhibitor and hyperosmotic agents. Phacoemulsification with IOL implantation (+28D) was performed 2 days later in LE. Postoperative outcome was positive; BCVA in the LE was 1 Snellen and IOP 16mmHg without treatment.

The third case we present is of a 42 year old hyperopic patient that presented for transient decrease of visual acuity. Patient history revealed OU angle closure glaucoma - peripheral laser iridotomy and LE trabeculectomy. RE BCVA was 1 Snellen, IOP 14mmHg with fixed combination beta-blocker and carbonic

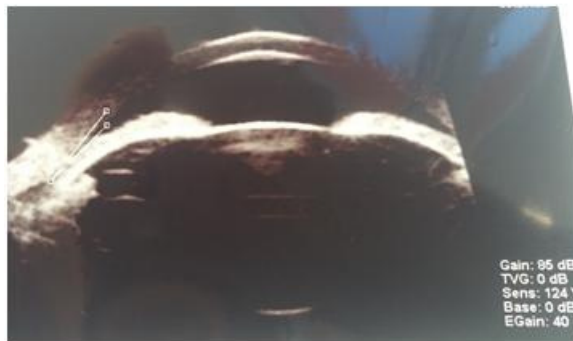


Figure 2. UBM showing shallow anterior chamber

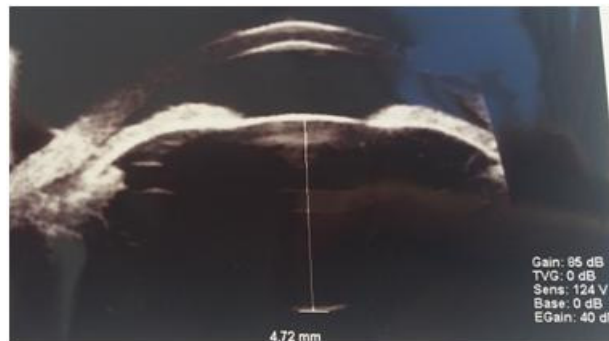

Figure 3. UBM showing increased sagittal lens volume

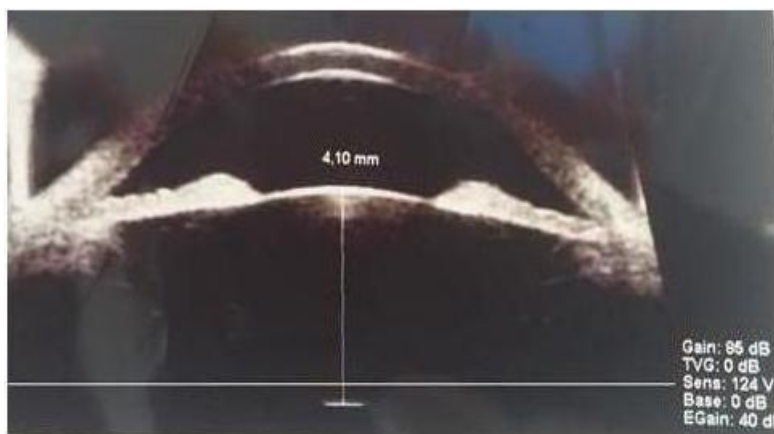


Figure 4. UBM showing increased sagittal lens volume prior to the surgery and postoperative aspect

anhydrase inhibitor and a c/d ratio of 0,6. LE BCVA was also 1/1, IOP 29mmHg with prostaglandin analogue, fixed combination beta-blocker and carbonic anhydrase inhibitor and c/d ratio 0,8. An UBM was performed and again, it showed a shallow anterior chamber with an increased sagittal lens volume (4.10 mm), (Figure 4), so we decided to proceed to lens extraction in the LE. After phacoemulsification and IOL implantation (+31D) IOP stabilised 13mmHg with fixed combination of beta-blocker and carbonic anhydrase inhibitor while BCVA remained 1 Snellen.

RESULTS

All our cases consisted of young hyperopic patients (+4D to +6D) with an axial length smaller than 22mm and a shallow anterior chamber. They associated a transparent lens with an increased sagittal diameter in report to the patient age and axial length. The diameter asymmetry was correlated to the IOP asymmetry and the degree of optic neuropathy suggesting an involvement of the lens in the pathogenesis of the disease.

Conservatory glaucoma treatment had a negative

outcome in some patients, resulting in malignant glaucoma, prolonged athalamia or choroidal detachment. However, lens extraction in these patients had a positive outcome, visual acuity remaining stabile or improving and the IOP stabilizing at a lower value.

Our results demonstrated that transparent lens can play a role in the mechanism of angle closure, and showed that clear lens extraction may act as an etiological treatment in such cases. Transparent lens extraction success depends on the time that is performed.

This confirms the theory that clear lens extraction could have a major role in the treatment of angle closure glaucoma opening the angle and creating a passage of the aqueous flow proving once again the importance of a proper examination of the lens in these patients.

DISCUSSIONS

Our study is consistent with other international studies that sustain the hypothesis that the lens extraction, a method that has been used as a treatment for glaucoma for many years, plays a major role in angle closure

glaucoma. Some studies even show that the postoperative IOP can be up to 1-12mmHg lower than the preoperative level (Lam et al, 2007; Vizzeri et al, 2010; Tham et al, 2009; Tarongoy et al, 2009; Jacobi et al, 2002; Lam et al, 2007; Roberts et al, 2000; Ming Zhi et al, 2003; Nonaka et al, 2005).

A Cochrane analyzes showed that there are no differences between lens extraction and other glaucoma therapies (Friedman et al, 2006). Nowadays the EAGLE study, a prospective study that investigates the possibility of using clear lens extraction as a treatment for angle closure glaucoma in patients with acute angle closure or chronic angle closure with MD less than -15dB and over 50 years old is undergoing (Azura-Blanco et al, 2006). However, we focused on a group of patients, usually females, younger than the ones from the EAGLE study that associate transparent lens with an enlarged sagittal diameter that induces angle closure. Clear lens extraction in these patients can play a decisive role in the management of the occult phacomorphic glaucoma.

In all the cases of primary angle closure glaucoma unresponsive to treatment is important to investigate the closure mechanism in order to determine the appropriate treatment for each particular case. The steps should include gonioscopy exam in order to explore the configuration of the angle and if the angle is open or closed, optical coherence tomography to investigate the report between the iris and the trabeculum and an UBM to evaluate the configuration of the lens and its possible role in the angle closure.

Recent considerations tend to focus on the lens involvement in the physiopathology of the disease and to incorporate the UBM in the investigations for angle closure glaucoma. This allows us to include in the treatment of phacomorphic glaucoma clear lens extraction in younger patients than the EAGLE study proposes.

In some cases the angle could appear open, but the configuration of the lens obstructs the trabeculum and makes the filtration difficult. The UBM helps us measure the sagittal diameter of the lens and its volume. If the lens is too large in rapport to the rest of the anterior segment, the patient could benefit from lens extraction.

Neglecting the lens factor in these patients and treating them as typical primary angle closure glaucoma could have a negative outcome on the long term. When trying a filtrating method we can end up with athalamia, malignant glaucoma, fluctuating IOP and an uncontrolled IOP.

Lens extraction in angle closure glaucoma is considered usually only after laser iridotomy and topical treatment fail.

Phacoemulsification should be performed at the right time, before IOP rise and the appearance of the glaucomatous optic neuropathy, but not before laser iridotomy. Gonioscopy, biometry and UBM can help us decide the right therapeutic option to each case.

CONCLUSIONS

1. In some cases of apparently primary open angle glaucoma unresponsive to treatment, with IOP values over 40 mmHg we need to consider the involvement of the lens in the pathogenesis of the disease.
2. There are transparent lenses with large sagittal diameter unrelated to intumescent cataracts, especially in hyperopic, young adults (4th-5th decade)
3. These patients can suffer an acute or chronic angle closure, sometime unresponsive to iridotomy, with unfavorable evolution . These hyperopic patients have a much higher lens sagittal diameter comparing to eye size, possibly the result of a quasi-permanent accommodative effort.
4. Neglecting lens involvement in these cases of glaucoma can lead to unfavorable evolution: atalamia, malignant glaucoma, abnormal IOP fluctuations, insufficient disease control.
5. In assessing CACG, it is recommended to measure lens parameters using biometry, UBM or OCT.
6. We can now confirm a repeatable clinical observation according to which clear lens extraction can have a major role in CACG evolution, by opening the angle or by making available small areas of the angle, capable to respond to topical medication .
7. Filtrating surgery prior to lens extraction , in these cases can lead to severe complications.

The increased lens sagittal diameter in a small eye allows us to call it "phacomorphic" involvement glaucoma and the normal, transparent, lens suggests its "occult" involvement. Glaucoma in such particular eyes, along with the association between the disease asymmetry and the sagittal lens diameters asymmetry supports our initiative to define the Occult Angle-Closure Glaucoma.

Competing Interests

The authors declare that there is no conflict of interests regarding the publication of this paper.

ACKNOWLEDGMENTS

All authors have equal contribution to and equal participation in the paper.

REFERENCES

- Aung T, Friedman DS, Chew PT, Ang LP, Gazzard G, Lai YF, Yip L, Lai H, Quigley H, Seah SK (2004). *Long-term outcomes in asians after acute primary angle closure*. s.l.: Ophthalmology, DOI: 10.1016/j.ophtha.2003.12.061.
- Azura-Blanco A, Burr J, Ramsay C, Cooper D, Foster PJ, Friedman DS, Scotland M, Javanbakht M, Cochrane C, Norrie J (2006).

- Effectiveness of early lens extraction for the treatment of primary angle-closure glaucoma (EAGLE): a randomised controlled trial.* s.l.: The Lancet, doi: 10.1016/S0140-6736(16)30956-4..
- Dhillon B, Chew PT, Lim AS (1990). *Field loss in primary angle closure glaucoma.* s.l.: Asia Pacific Journal of Ophthalmology, 85-87.
- Friedman DS, Vedula SS (2006). *Lens extraction for chronic angle closure glaucoma.* s.l.: Cochrane Database of Systematic Reviews
- Gordon RD, Stephen MD, Michael S (1975). *The Visual Field and Nerve Head in Angle-Closure Glaucoma. A Comparison of the Effects of Acute and Chronic Angle Closure.* s.l.: Arch Ophthalmol., doi:10.1001/archophth.1975.01010020423004.
- Heys JJ, Barocas VH, Taravella MJ (1999). *Modeling passive mechanical interaction between aqueous humor and iris.* s.l.: Journal of Biomechanical Engineering, doi:10.1115/1.1411972.
- Lam DS, Leung DY, Tham CC, Li FC, Kwong YY, Chiu TY, Fan DS (2008). *Randomized trial of early phacoemulsification versus peripheral iridotomy to prevent intraocular pressure rise after acute primary angle closure.* s.l.: Ophthalmology, DOI: 10.1016/j.ophtha.2007.10.033.
- Lowe RF (1969). *Causes of shallow anterior chamber in primary angle-closure glaucoma. Ultrasonic biometry of normal and angle-closure glaucoma eyes.* s.l.: Am J Ophthalmol, Jan;67(1):87-93..
- Ming Zhi Z, Lim AS, Yin Wong T (2003). *A pilot study of lens extraction in the management of acute primary angle-closure glaucoma.* s.l.: Am J Ophthalmol., DOI: [http://dx.doi.org/10.1016/S0002-9394\(02\)02108-6](http://dx.doi.org/10.1016/S0002-9394(02)02108-6).
- Nonaka A, Kondo T, Kikuchi M, Yamashiro K, Fujihara M, Iwawaki T, Yamamoto K, Kurimoto Y (2006). *Angle widening and alteration of ciliary process configuration after cataract surgery for primary angle closure.* s.l.: Ophthalmology, DOI: <http://dx.doi.org/10.1016/j.ophtha.2005.11.018>.
- Nongpiur ME, He M, Amerasinghe N, Friedman DS, Tay WT, Baskaran M, Smith SD, Wong TY, Aung T (2011). *Lens vault, thickness, and position in Chinese subjects with angle closure.* s.l.: Ophthalmology, DOI: 10.1016/j.ophtha.2010.07.025.
- Philipp C Jacobi, MD Philipp C Jacobi, Thomas S Dietlein, MD, Christoph Lüke, MD, Bert Engels, MD, Günter K Krieglstein, MD (2002). *Primary phacoemulsification and intraocular lens implantation for acute angle-closure glaucoma 1.* s.l.: Ophthalmology, DOI: [http://dx.doi.org/10.1016/S0161-6420\(02\)-01123-5](http://dx.doi.org/10.1016/S0161-6420(02)-01123-5).
- Reay H. Brown, MD. *Lens Extraction in Angle-Closure Glaucoma.* s.l.: Glaucoma Today, 2015. vol13, no2.
- Rosman M1, Aung T, Ang LP, Chew PT, Liebmann JM, Ritch R (2002). *Chronic angle-closure with glaucomatous damage: long-term clinical course in a North American population and comparison with an Asian population.* s.l.: Ophthalmology, DOI: [http://dx.doi.org/10.1016/S0161-6420\(02\)01275-7](http://dx.doi.org/10.1016/S0161-6420(02)01275-7).
- Tarongoy P, Ho CL, Walton DS (2009). *Angle-closure glaucoma: the role of the lens in the pathogenesis, prevention, and treatment.* s.l.: Surv Ophthalmol., doi: 10.1016/j.survophthal.2008.12.002..
- Tham CC, Kwong YY, Leung DY, Lam SW, Li FC, Chiu TY, Chan JC, Lam DS, Lai JS (2009). *Phacoemulsification versus combined phacotrabeculectomy in medically uncontrolled chronic angle closure glaucoma with cataracts.* s.l.: Ophthalmology., DOI: 10.1016/j.ophtha.2008.12.054.
- Timothy V Roberts, Ian C Francis, Sam Lertusumitkul, Medduma B Kappagoda, Minas T Coroneo (2000). *Primary phacoemulsification for uncontrolled angle-closure glaucoma.* s.l.: Journal of Cataract and Refractive Surgery, [http://dx.doi.org/10.1016/S0886-3350\(00\)00358-8](http://dx.doi.org/10.1016/S0886-3350(00)00358-8).
- Vizzeri G, Weinreb RN (2010). *Cataract surgery and glaucoma.* s.l.: Curr Opin Ophthalmol, DOI: 10.1097/ICU.0b013e328332f562.
- Wang BS, Narayanaswamy A, Amerasinghe N, Zheng C, He M, Chan YH, Nongpiur ME, Friedman DS, Aung T (2011). *Increased iris thickness and association with primary angle closure glaucoma.* s.l.: British Journal of Ophthalmology., DOI: 10.1136/bjo.2009.178129.
- Yeon-Hee L, Chang-Sik K, Sung-pyo H (2004). *Rate of Visual Field Progression in Primary Open-angle Glaucoma and Primary Angle-closure Glaucoma.* Korean J Ophthalmol. <https://doi.org/10.3341/kjo.2004.18.2.106>.
- Yih-Chung T, Xiang L, Tien YW, Harry AQ, Tin A, Ching-Yu C, Ching-Yu C (2014). *Global Prevalence of Glaucoma and Projections of Glaucoma Burden through 2040.* s.l.: Ophthalmology, DOI: <http://dx.doi.org/10.1016/j.ophtha.2014.05.013>.
- Yip LW, Aquino MC, Chew PT (2007). *Measurement of anterior lens growth after acute primary angle-closure glaucoma.* s.l.: Canadian Journal of Ophthalmology. DOI: <http://dx.doi.org/10.3129/can.jophthalmol.i07-008>.