

Original Research Article

Surgical Outcome of Lower Lip Reconstruction Using the Webster Flap

Wael Hussein Mahmoud M. D.

Abstract

Plastic, Reconstructive Surgery and Burns Department, Tanta Faculty of Medicine, Tanta, Egypt

E-mail:
waelhussein_558@yahoo.com
Tel.: +2 0100 27 999 61

Due to complex functional and cosmetic importance of the lips, the reconstruction of the resulting lip defects has always been a challenge for reconstructive surgeons. Many surgical techniques have been described in the literature to reconstruct such defects; each has its own advantages and disadvantages. We aimed in this study to evaluate the use of the Webster flap in reconstruction of large full-thickness lower lip defects after tumor resection with regard to functional and esthetic outcomes. A prospective study was conducted between Feb 2013 and Feb 2016 on 15 patients (9 males, 6 females), with mean age of 60.7 years, with large full-thickness lower lip defects following resection of SCC and were reconstructed by the Webster flap (3 unilateral and 12 bilateral flaps). The commissure was involved in 6 patients (40%). All patients were evaluated for early postoperative wound complications and for late results regarding the functional aspect of the repair in terms of oral competence and size of the oral stoma. As for esthetic outcome, objective assessment was done and graded as excellent, good and poor. Routine oncologic follow up was done for all patients. All flaps survived completely, while minor cutaneous dehiscence occurred in 2 patients (13.3%). None of our patients developed microstomia. Six patients (40%) developed temporary incontinence to oral fluids and two patients (13.3%) had drooling. Complete recovery of all functional changes occurred within 8-10 weeks. The final esthetic outcome was excellent in 5 patients (33.3%), good in 8 patients (53.3%) and poor in 2 patients (13.3%). The follow up period ranged from 6 to 24 months (mean - 13.8 m). We can conclude that the Webster flap is highly effective single-stage procedure for reconstruction of large full-thickness lower lip defects, which has the advantages of preservation of oral competence and maintenance of adequate mouth opening. Moreover, it provides good esthetic outcomes at rest and function.

Keywords: Large Full-thickness Defects, Lower Lip Reconstruction, Webster Flap

INTRODUCTION

The lips are the key esthetic feature of the lower third of the face (Denadai et al., 2015). They play a vital role in the individual's self-esteem and appearance as well as in many functional requirements including the oral competence, speech and communication of emotion (Baumann and Robb, 2008). The lips are critical in pronunciation of the labial sounds "m," "b," "p" and "w", in addition to the labial-dental sounds "v" and "f" (Cupp and Larrabee, 1993). Lip defects can result from many pathologies such as tumors, trauma, burns, vascular

malformations and infectious diseases (Oliveira et al., 2011), with oncologic resection of malignant neoplasia being the main cause of large lip defects (Anvar et al., 2007). Squamous cell carcinoma is the most frequent malignant neoplasm of the lips (95%) with 90% of the cases occurring in the lower lip (Emil et al., 2008).

Due to complex functional and esthetic importance of the lips, the reconstruction of the resulting lip defects presents a challenge for reconstructive surgeons (Siqueiral et al., 2012), and whenever possible should

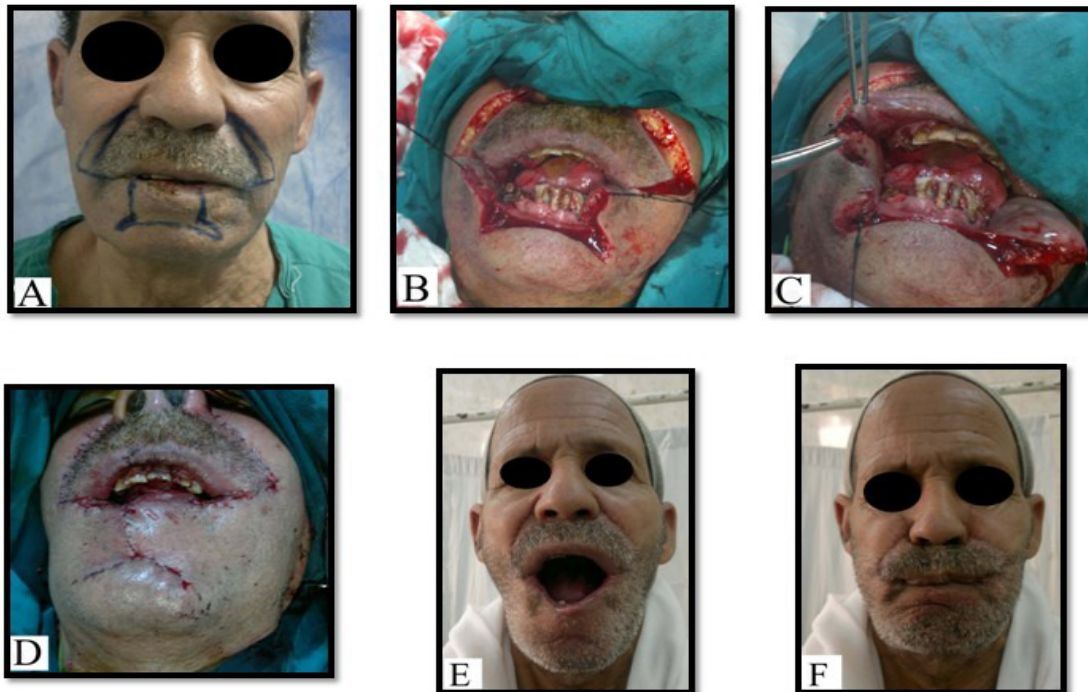

Figure 1. A 69-year old male with SCC affecting about 2/3 of the lower lip underwent bilateral Webster flaps. (A). Pre-operative flap design. (B). Intra-operative view shows full layer excision of the tumor with 1cm safety margins and excision of the two Burrow's triangles of skin and subcutaneous tissue. (C). Intra-operative view shows mucosal flaps that used for reconstruction of the vermilion. (D). Intra-operative view after the two flaps were advanced medially. (E). (F). Four months post-operative view shows good functional and esthetic outcomes.

aim to maintain the sphincter function, preserve adequate mouth opening and achieve an esthetically pleasing skin coverage (Memon et al., 2008). There are several reconstructive techniques to be selected from, according to location and size of the defect and availability of adjacent tissues (Ebrahimi et al., 2011). Although, most Plastic Surgeons choose tissues for lip reconstruction from the remaining lip tissues followed by the opposite lip then the adjacent cheek and finally distant tissues, it is difficult for them to select the ideal reconstructive method (Rifaat, 2006).

In 1853, Camille Bernard (Bernard, 1853) proposed a technique that entails excising of four full-thickness triangles (Burrow's triangles) from the bases of bilateral cheek advancement flaps. Although the entire lower lip was resurfaced by these advancement sliding flaps, poor sensation and function were noticed due to transects of perioral muscles. This technique was modified by Webster et al. (1960), where the triangular excisions were limited to the skin only to safeguard the deep neuromuscular anatomy, while the mucosal flaps were used to reconstruct lip vermilion. Since then the Webster flap has been used for reconstruction of lower lip defects. In this study we aimed to evaluate the use of the Webster flap in reconstruction of large full-thickness lower lip defects after tumor resection with regard to functional and esthetic outcomes.

MATERIALS AND METHODS

In the period from February 2013 to February 2016, a prospective study was conducted in the Plastic, Reconstructive Surgery and Burns Department, Tanta University Hospitals on 15 patients (9 males and 6 females) who had large full-thickness lower lip defects following resection of malignancy and were reconstructed by the Webster flap (3 unilateral and 12 bilateral flaps). Their age ranged from 40 to 72 years (mean-60.7years). Three patients (20%) had defects equal to one half of the lip, ten (66.7%) had defects about two thirds of the lip and two (13.3%) had near total lip loss. The commissure was involved in 6 patients (40%).

After being approved by the Ethics committee of Tanta Faculty of Medicine, all patients were subjected to thorough history taking, full clinical examination, incisional biopsy and metastatic work up to detect type of the tumor, status of the cervical lymph nodes and the presence of loco-regional or distant metastasis. A written informed consent was taken from all patients.

Operative technique

First, the flaps were marked (Figure 1a) with the bases of the Burrow's triangles on the line drawn horizontally and

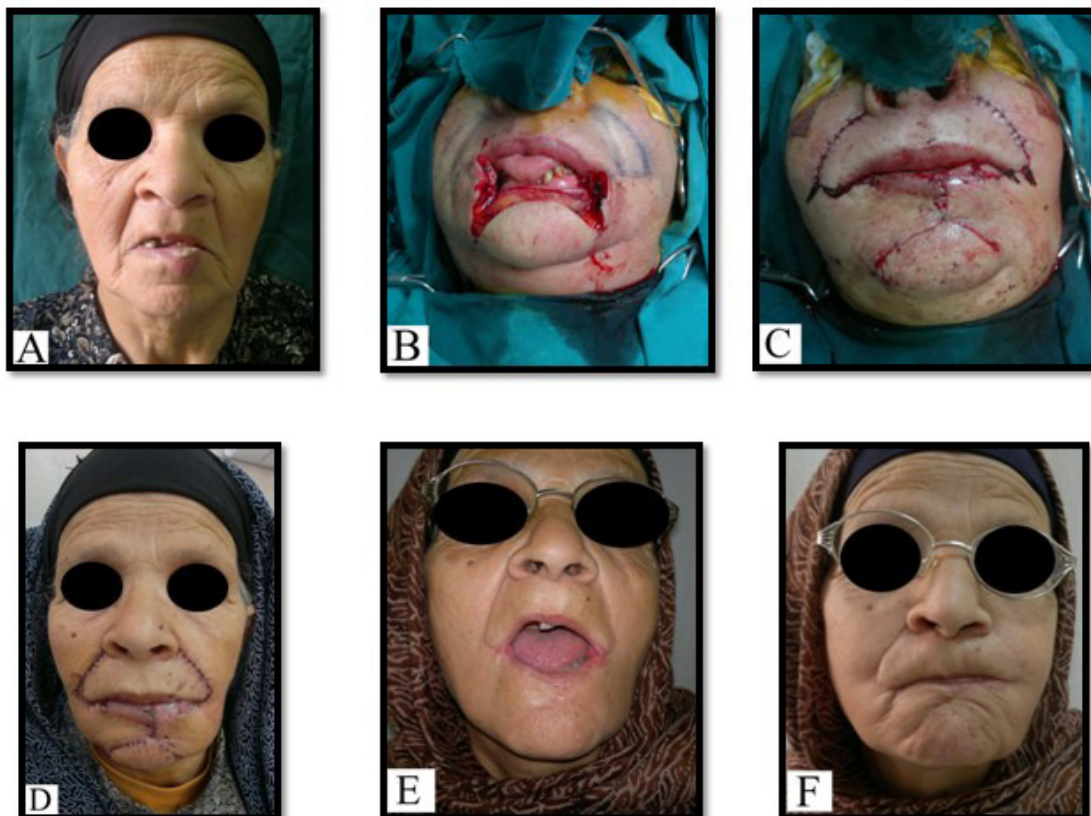

Figure 2. A 68-year old female with SCC affecting about 2/3 of the lower lip underwent bilateral Webster flaps. (A). Pre-operative picture. (B). Intra-operative view shows full layer excision of the tumor with 1cm safety margins. (C). Intra-operative view after the two flaps were advanced medially (D). Early post-operative picture. (E). (F). Five months postoperative view shows good functional and esthetic outcomes.

slightly superiorly from the labial commissure and should be from one half to one third of the transverse diameter of the lip defect. The apices and the medial sides of the Burrow's triangles on the melolabial sulcus, while their lateral sides connecting the apices to the horizontal line of the commissure. All operative procedures were done under general anesthesia with nasotracheal intubation. We performed full layer excision of the tumor with 1cm safety margins in a quadrilateral shape with its lower border in the labiomental groove. Thereafter, we made incisions in the marked area to excise the two Burrow's triangles of skin and subcutaneous tissue down to the muscle layer. (Figure 1b) The lower mucous membrane incisions were situated 0.5 cm above the alveolo-buccal groove, while the upper mucous membrane incisions were made about 1cm above the labial commissure and below the orifices of Stensen's ducts to create flaps from oral mucosa that used for reconstruction of the vermilion. (Figure 1c)

We didn't transect the orbicularis oris muscle at the level of the commissure. After cutaneous and mucous incisions were completed the flap mobility was checked and if necessary, the muscles were incised below the mental neurovascular bundle level or the muscles lateral to commissure were incised to assist in flap advancement

then sutured to create a new commissure. The flaps were advanced medially and the muscles approximated and sutured at the midline with mattress sutures. The intra-oral mucosal flaps were flipped over to create the lacking vermilion then the rest of the mucosa were closed in water tight fashion. The operation was completed by skin closure with simple interrupted sutures. (Figure 1d) This procedure can be done bilaterally (Figure 2) or unilaterally (Figure 3) with defects located mainly at the central or lateral parts of the lip respectively.

Post-operative care and monitoring

All patients were discharged on the 5th postoperative day and instructed to eat soft diets and avoid wide opening of the mouth for 3 weeks. Sutures were removed 10-14 days after surgery. The patients were asked to come for postoperative follow up once monthly for six months, then every 3 months for 2 years. All patients were evaluated for early postoperative complications in terms of hematoma, flap necrosis, infection, dehiscence and oro-cutaneous fistula and for late results regarding the functional aspect of the repair in terms of preservation of the oral competence and size of the oral stoma. As for

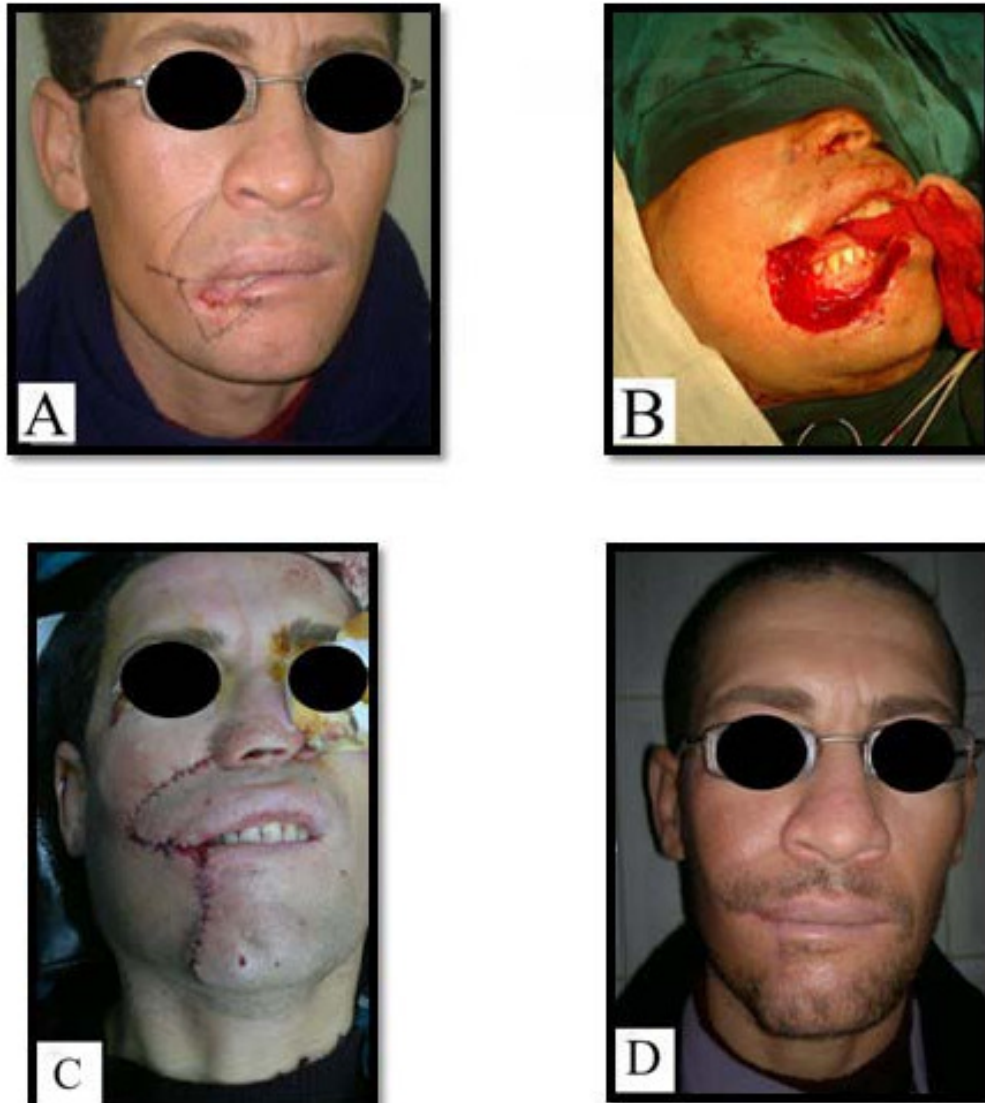


Figure 3. A 40-year old male with SCC affecting about 1/2 of the lower lip with commissure involvement underwent right unilateral Webster flap (A). Pre-operative picture. (B). Intra-operative view shows full layer excision of the tumor with 1cm safety margins. (C). Intra-operative view after complete wound closure. (D). Three months post-operative view shows good functional and esthetic outcomes.

esthetic outcome, objective assessment was done by another two Plastic Surgeons and was graded as excellent, good and poor. Routine oncologic follow up was done for all patients.

RESULTS

Over a 3 year period, fifteen patients with large full-thickness lower lip defects (range from half to near total lip loss) after surgical resection of squamous cell carcinoma (SCC) were reconstructed by 27 Webster flaps (3 unilateral and 12 bilateral flaps). Three patients (20%) were classified as $T_2N_0M_0$ while twelve (80%) were classified as $T_3N_0M_0$ according to the "7th American Joint

Committee on Cancer Staging Manual". The patients' summarized data and their outcomes are shown in Table 1.

There was complete survival of all flaps and the postoperative period was uneventful in 13 patients (86.7%), while minor cutaneous dehiscence occurred in two patients (13.3%). They were treated conservatively and healed by secondary intention within 3 weeks. With regards to functional outcome, none of our patients developed microstomia. As for oral continence, six patients (40%) developed temporary incontinence to oral fluids which could be attributed to their commissure involvement and two patients (13.3%) had drooling which could be explained by the wound dehiscence. Complete recovery of all functional changes occurred within 8-10

Table 1. Patients ' data and outcomes

No.	Age(yr)/Sex	Size	Relation to commissure	Reconstructive procedure	Wound complications	Functional outcome		Esthetic outcome	Follow-up(mo)
						Microstomy	Oral continence		
1	69/M	2/3	Not involved	Bilat Webster	No	No	Continent	Excellent	18
2	49/M	Near total lip loss	Not involved	Bilat Webster	Partial dehiscence	No	Drooling	Poor	24
3	60/F	2/3	Involved	Bilat Webster	No	No	Fluid incontinence	Good	15
4	64/F	2/3	Not involved	Bilat Webster	No	No	Continent	Good	9
5	65/F	2/3	Not involved	Bilat Webster	No	No	Continent	Excellent	12
6	40/M	1/2	Involved	Rt Unilat Webster	No	No	Fluid incontinence	Good	9
7	62/M	2/3	Not involved	Bilat Webster	No	No	Continent	Excellent	12
8	68/F	2/3	Involved	Bilat Webster	No	No	Fluid incontinence	Good	12
9	65/M	Near total lip loss	Not involved	Bilat Webster	Partial dehiscence	No	Drooling	Poor	21
10	58/M	2/3	Involved	Bilat Webster	No	No	Fluid incontinence	Good	18
11	60/M	1/2	Involved	Lt Unilat Webster	No	No	Fluid incontinence	Good	9
12	72/F	2/3	Not involved	Bilat Webster	No	No	Continent	Excellent	9
13	50/F	2/3	Not involved	Bilat Webster	No	No	Continent	Good	18
14	60/M	1/2	Involved	Rt Unilat Webster	No	No	Fluid incontinence	Good	15
15	68/M	2/3	Not involved	Bilat Webster	No	No	Continent	Excellent	6

weeks. The final esthetic outcome as detected by the objective assessment was excellent in 5 patients (33.3%), good in 8 patients (53.3%) and poor in 2 patients (13.3%). The follow up period ranged from 6 to 24 months (mean -13.8 m). None of our patients developed distant metastasis or local recurrence till the end of the postoperative follow up period.

DISCUSSION

Functional and esthetic reconstruction of the lip defects has constantly been a challenge. From

the anatomic point of view lip defects could be classified into; full-thickness defects, simple skin defects and vermilion defects. With exception of leucoplakia and carcinoma in situ, radical excision of lip carcinoma with tumor free margins results invariably in full-thickness defects (Kornevs et al., 2005). Generally, for small defects up to one third of the lower lip, primary closure following V-shaped, W-shaped or barrel shaped excision is a relatively simple and effective method (Seo et al., 2013). On the other hand, defects greater than one third of the lower lip require more deliberate surgical planning to preserve competent oral sphincter, maintain adequate stomal diameter,

achieve complete oral lining and skin cover and restore lip cosmesis. Many surgical techniques have been described in the literature to reconstruct such defects; each has its own advantages and limitations (Cupp and Larrabee, 1993; Siqueiral et al., 2012; Mohamed and EL-swaify, 2008).

According to Luce (1995), lower lip defects from 30 to 65% are best repaired by cross lip techniques, while for defects from 65 to 80% Karapandzic and Webster flaps are of choice. As for defects > 80% free composite flaps are necessary. Although the Abbe flap can replace the missing labial tissue by "like with like" and

without distortion of the commissure or additional facial scarring, it is a two-stage surgery and there is a risk of lip vermilion misalignment and microstomy in large defects (Eskiizmir et al., 2012). The Estlander flap used for commissure involving defects. However, a second surgery is frequently needed for commissuroplasty (Anvar et al., 2007). The Gilles fan flap has the advantage of maintaining the continuity of the orbicularis oris muscle and can be used bilaterally for closure of large defects but being completely denervated and microstomia are major handicaps (Galyon and Frodel, 2001). The Karapandzic flap has been successfully used for reconstruction of large lower lip defects, providing the patient with sensate, mobile and competent lip but is limited by modiolus displacement, rounding of the commissure and microstomy that may need a secondary procedure (Patel et al., 2015).

Distant flaps have been used to resurface extensive defects with total lip loss especially when nearby local tissues aren't available. Although pectoralis major myocutaneous flap and deltopectoral flap can effectively be used to cover such defects, they have poor sphincter function (Mohamed and EL-swaify, 2008). The free radial forearm flap especially when the Palmaris tendon included offers flexibility in size and maintenance of oral competence but is limited by the difference of the skin color between the recipient and the donor sites, the need for microsurgical facilities and donor site morbidity (Jeng et al., 2004). We aimed in this study to evaluate the use of the Webster flap in reconstruction of large full-thickness lower lip defects after tumor resection with regard to functional and esthetic outcomes.

In our series, we used 27 Webster flaps (12 bilateral and 3 unilateral flaps) to treat 15 patients with full-thickness lower lip defects secondary to SCC resection. The defects were \geq half of the length of the lower lip with commissure involvement in 40% of the cases. Similar to our study and findings, Denadai et al (2015) used 11 Webster flaps (5 bilateral and 1 unilateral flaps) to treat 6 patients with full-thickness defects of the lower lip after SCC resection. The defects were more than one third of the lower lip's length, located in the central portion of the lip in five patients and in the lateral portion in one patient and none of the lesions involved the lip commissure. They concluded that, the Webster flap is an excellent method for reconstruction of full-thickness lower lip defects greater than 1/3 of the lip's length. Contrary to us, Brinca et al. (2011) used Karapandzic flap and Webster flap for reconstruction of large lower lip defects after surgical excision of tumors and concluded that, although the Webster flap didn't cause microstomy, it caused incontinence of the oral sphincter and misplacement of the lower lip position.

In this study, all flaps survived completely and there was minor cutaneous dehiscence in 2 patients (13.3%) that were treated conservatively. In a similar study, Rifaat (2006) found that, there was complete survival of all

flaps, while minor wound breakdown was detected in 3 cases (16.7%) only and healed spontaneously. In another study, Memon et al., (2008) noticed that, the partial wound breakdown that occurred in 3 cases (3.9%) resulted in noticeable lip notching and required surgical repair by addition of Abbe flaps.

This series witnessed that, none of our patients developed microstomy, six patients (40%) had temporary fluid incontinence, two patients (13.3%) had temporary drooling and complete functional recovery occurred within 8-10 weeks. In agreement with us, Seo et al. (2013) observed that, two patients (7.7%) had drooling, four patients (15.4%) had parasthesia, complete recovery of all functions occurred within 3 months and all the patients showed good functional and esthetic treatment outcomes. Unlike our findings, James et al. (2006) noted that, the Webster flap may lead to alteration of the kinetics of the smiling and reduction of the mouth opening from scarring.

Our study showed that, the final esthetic outcome was excellent in five patients (33.3%), good in eight patients (53.3%) and poor in two patients (13.3%) which is consistent with that of Uzunov et al. (2013) who found that, the scars were hardly discoverable within 6-9 months and all the patients were satisfied with the scar fading, the facial appearance and the improvement of the lip competence. They concluded that, the Webster flap is a useful technique for subtotal and total lower lip reconstruction. Our findings confirmed Denadai et al. (2015) who reported that, one patient (16.7%) had liquid incontinence, another patient (16.7%) had salivary incontinence, none of the patients had microstomy, total recovery of all functional changes occurred within 3 months and all the patients were pleased with the esthetic and functional results. In another study, Korenevs et al. (2005) observed that, the initial results of the Webster flap may be satisfactory. However, the continuous tension of the closure may lead to tightening of the lower lip that adversely affects its function. Therefore, we recommend for a longer follow up period on a larger group of patients for better evaluation of the esthetic and functional outcomes.

CONCLUSION

We believe that the Webster flap is highly effective single-stage procedure for reconstruction of large full-thickness lower lip defects, which has the advantages of preservation of oral competence and maintenance of adequate mouth opening. Moreover, it provides good esthetic outcomes at rest and function.

REFERENCES

- Anvar BA, Evans BC, Evans GR (2007). Lip reconstruction. *Plast Reconstr Surg*, 120(4):57e-64e

- Baumann D, Robb G (2008). Lip reconstruction. *Semin Plast Surg*, 22(4):269-80
- Bernard C (1853). Cancer de la levre inferieur opere par un procede nouveau. *Bull Soc Chir Paris*, 3:357-60
- Brinca A, Andrade P, Vieira R, Figueiredo A (2011). Karapandzic flap and Bernard-Burrow-Webster flap for reconstruction of the lower lip. *An Bras Dermatol*, 86(4):156-9
- Cupp CL, Larrabee WF (1993). Reconstruction of the lips. *Oper Tech Otolaryngol-Head Neck Surg*, 4(1):46-53
- Denadai R, Sarmiento GS, Buzzo CL, Raposo-Amaral CE, Raposo-do-Amaral (2015). Use of Bernard-Webster flap for lower lip reconstruction after excision of squamous cell carcinoma: analysis of functional results. *Rev Bras Cir Plást*, 30(1):8-17.
- Ebrahimi A, Maghsoudnia GR, Arshadi AA (2011). Prospective comparative study of lower lip defects reconstruction with different local flaps. *J Craniofac Surg*, 22(6):2255-9
- Emil D, Ivica L, Miso V (2008). Treatment of squamous cell carcinoma of the lip. *Coll Antropol*, 32(2):199-202
- Eskiizmir G., Baker S., Cingi C (2012). Nonmelanoma skin cancer of the head and neck: reconstruction. *Facial Plast Surg Clin North Am*, 20(4):493-513
- Galyon SW, Frodel JL (2001). Lip and perioral defects. *Otolaryngol Clin North Am*, 34: 647
- James JC, Anthony MP, Brian LS (2006). Reconstruction of perioral defects following resection for oral squamous cell carcinoma. *J Oral Maxillofac Surg*, 64: 367-74
- Jeng SF, Kuo YR, Wei FC, Su CY, Chien CY (2004). Total lower lip reconstruction with a composite radial forearm palmaris longus tendon flap: A clinical series. *Plast Reconstr Surg*, 113: 19-23
- Kornevs E, Skagers A, Tars J, Bigestans A, Lauskis G, Libermanis O. (2005). 5 year experience with lower lip cancer. *Stomatologija*, 7(3):95-8
- Luce EA (1995). Reconstruction of the lower lip. *Clin Plast Surg*, 22(1):109-21
- Memon AR, Tahir SM, Shaikh BF (2008). Outcome of reconstruction of lower lip squamous cell carcinoma in different treatment modalities. *Pakistan J Surg*, 24(4):261-5
- Mohamed AM, EL-swaify GA (2008). Perioral Defects: Reconstructive Techniques. *Egypt J Plast Reconstr Surg*, 32(1): 5-12,
- Oliveira MP, Martins PDE, Cunha GL, Alvare z GS, Gazzalle A, Siqueira EJ (2011). Use of the vermillion myomucosal flap with or without the mentolabial skin flap for lower lip reconstruction. *Rev Bras Cir Plást*, 26(3):433-8
- Patel KNA, Dandgi S, Singh R (2015). Lip Reconstruction using Karapandzic Flap. *World J Dentistry*, 6(1):55-7
- Rifaat MA (2006). Lower Lip Reconstruction after Tumor Resection; a Single Author's Experience with Various Methods. *J Egyptian Nat Cancer Inst*, 18(4): 323-33
- Seo HJ, Bae SH, Nam SB, Choi SJ, Kim JH, Lee JW, Bae YC. (2013). Lower lip reconstruction after wide excision of a malignancy with barrel-shaped excision or the webster modification of the bernard operation. *Arch Plast Surg*, 40(1):36-43
- Siqueiral EJ, Alvarez GS, Laitano FF, Martins DPE, Oliveira MP (2012). Lower lip reconstruction strategies. *Rev Bras Cir Plást*, 27(4):536-41
- Uzunov N, Trifonov M, Vicheva D, Nedev P (2013). Our experience with total and subtotal lower lip reconstruction using modified Webster's cheek advancement flaps after cancer resection. *Otorhinolaryngologia - Head Neck Surge*, 54:16-19
- Webster RC, Coffey RJ, Kelleher RE (1960). Total and partial reconstruction of the lower lip with innervated musclebearing flaps. *Plast Reconstr Surg Transplant Bull*, 25(3):360-71