

Original Research Article

Clinical signs and pathologic lesions of highly pathogenic avian influenza in Indonesia: A threat to Indonesian poultry

R. Wasito^{1*}, Hastari Wuryastuti¹, Rachmat Pambudy² and Roger K. Maes³

Abstract

¹Faculty of Veterinary Medicine,
Gadjah Mada University, Yogyakarta,
Indonesia

²Faculty of Animal Husbandry, Institut
Pertanian, Bogor, Indonesia

³Virology Section, Department of
Microbiology and Public Health,
College of Veterinary Medicine,
Michigan State University, E. Lansing,
MI, USA

*Corresponding Author's E-mail:
wst_ugm@yahoo.com

We have studied the clinical signs and pathological lesions responsible for the property characteristic of primary avian influenza type A H5N1 subtype during the 2003 to 2005 outbreaks of the H5N1 influenza viruses in Indonesia. The highest number affected flocks were in layer chickens, with only limited number of quail flock, backyard chicken flock, ducks flock and live-bird markets infected. Those poultry originated from provinces in East Java, West Java, Central Java and Yogyakarta. Depression and droopiness, loss of appetite, sudden drop in egg production, neurologic dysfunction, respiratory distress and diarrhoea were common clinical signs manifestations of the avian influenza infection. Grossly, the most severe and consistent lesions included cyanosis (purplish-blue coloring) of wattles and comb, edema and swelling of head, eyelids, comb, and hemorrhages in the skeletal muscles and feet. Interestingly enough that the quails had only a severely decreased in the general condition and food intakes, and also showed neurologic disorders and diarrhoea. Grossly, the quail lacked significant gross lesions as those seen in the chickens. The clinical signs and pathologic anatomic lesions were analogous to those experimentally induced with other highly pathogenic avian influenza viruses in domestic poultry.

Keywords: Avian influenza, H5N1, clinical signs, pathological lesions, Indonesian poultry

INTRODUCTION

Avian influenza virus is classified within the genus Influenza virus A of the family of Orthomyxoviridae (Lamb and Krug, 1996). There are many strains of avian influenza virus that can cause varying amounts of clinical signs and pathological lesions in poultry. AI viruses can be classified into low pathogenic (LPAI) and highly pathogenic (HPAI) forms based on the severity of the diseases they cause. Most AI virus strains are LPAI and typically cause little or no clinical signs in infected poultry. However, some LPAI virus strain are capable of mutating under field conditions into HPAI viruses. HPAI is an extremely infectious and fatal form of the disease. HPAI

can strike poultry quickly without any infection warning signs. Once established, the disease can spread rapidly from flock to flock (Anonymous, 2002). All 16 known influenza A virus hemagglutinin (HA) subtypes can be isolated in avian species. Only the H5 and H7 HA subtypes are considered to be highly pathogenic in avian species, having shown pantropic dissemination within the host (Bosch *et al.*, 1981; Kawaoka *et al.*, 1987). AI viruses can infect chickens, turkeys, pheasants, quail, ducks, geese and guinea fowl, as well as a wide variety of other birds. Migratory waterfowls have proved to be the natural reservoir for this disease. Pigs are permissive to



Figure 1.

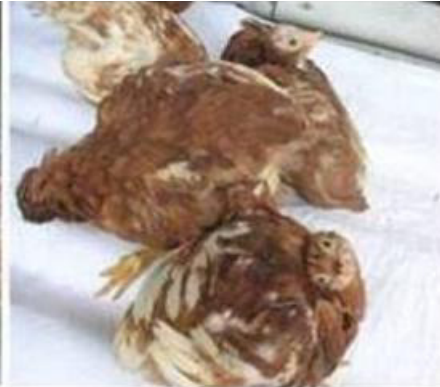

Figure 2.

Figures 1 and 2. Nervous disorders of chickens having avian influenza. Torticollis and curled toe paralysis.

both human and avian influenza viruses and have been proposed to be an intermediate host for the genesis of pandemic influenza viruses through re-assortment or adaptation of avian viruses (Peiris *et al.*, 2001). Prospective research carried out between June to December 2005 in the Laboratory of Immunology and Molecular Biology, The Animal Hospital, Faculty of Veterinary Medicine, Gadjah Mada University, Yogyakarta, Indonesia, provides the first evidence of flies (*Musca domestica*) had the avian influenza virus H5N1 (Wuryastuti *et al.*, 2005). However, direct evidence that flies may play a critical role on the transmission of avian H5N1 viruses to poultry and even to human is still lacking.

Morbidity and mortality rates are as variable as the signs and are dependent on the species and virus, as well as age, environment, and concurrent infections (Easterday *et al.*, 1997). Clinical signs vary greatly and depend on many factors including the age and species of poultry affected, husbandry practices, and the inherent pathogenicity of the influenza virus strain. Clinical signs may include ruffled feathers, soft-shelled eggs, depression and droopiness, sudden drop in egg production, loss of appetite, cyanosis (purplish-blue coloring) of wattles and comb, edema and swelling of head, eyelids, comb, wattles and hocks, diarrhea, blood-tinged discharge from nostrils, incoordination, including loss of ability to walk and stand, pin-point hemorrhages (most easily seen on the feet and shanks), respiratory distress and increased death in a flock. The clinical signs of avian influenza are similar to those of other avian diseases. Avian influenza may be confused with infectious bronchitis, infectious laryngotracheitis, fowl cholera, and the various forms of Newcastle disease (Jacob *et al.*, 2003).

Postmortem lesions vary greatly depending on pathogenicity of the virus, age of the birds, and type of poultry. Lesions may include swelling of the face and area below the beak. Removing skin from the carcass will

show a clear straw-colored fluid in the subcutaneous tissues. Blood vessels are usually engorged. Hemorrhage may be seen in the trachea, proventriculus, beneath the lining of the gizzard, and throughout the intestines. The lining of the gizzard may be easily removed. Other areas likely to show swelling and hemorrhages include the muscle along the breast bone as well as in the heart, gizzard fat and abdominal fat (Jacob *et al.*, 2003).

MATERIALS AND METHODS

Sampling of poultry

Sampling was carried out in the Laboratory Pathology and Animal Hospital, Faculty of Veterinary Medicine, Gadjah Mada University, Yogyakarta, Indonesia. The poultry collected between October 2003 to December 2005 on a daily basis from poultry submitted at the Faculty of Veterinary Medicine, Gadjah Mada University. The total sample incorporated about 100 farms consisted of layer chicken (80%), quail (14%), backyard chicken (5%) and ducks and live-bird markets (1%). Those samples originated from provinces in East Java, West Java, Central Java and Yogyakarta.

RESULTS

In the present study, mostly only severe changes in the clinical signs appearances of the poultry were observed. The typical clinical signs manifested by poultry infected with highly pathogenic avian influenza viruses include respiratory signs, rales, edema of the head and face, nervous system disorders (Figures 1-2). Cyanosis of unfeathered skin (especially the combs and wattles), decreased egg production, diarrhea, excessive lacrimation and sinusitis were also observed. In layer

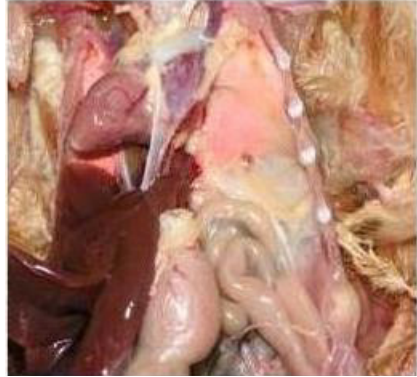


Figure 3.

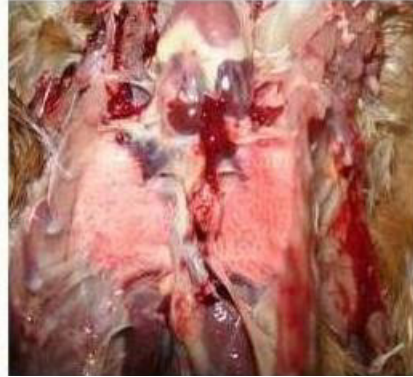

Figure 4.

Figures 3 and 4. Pulmonary swollen and petechial hemorrhages of the chickens having avian influenza infection.

chickens, the ovary may be hemorrhagic.

The swollen and petechial hemorrhages may be seen in the lungs (Figures 3-4) in all poultry examined.

DISCUSSION

Avian influenza is an infectious disease of birds caused by type A strains of the influenza virus disease, which was first identified in Italy more than 100 years ago, occurs worldwide (Webster and Kawaoka, 1988; Easterday *et al.*, 1997). Many domestic and wild poultry species are infected with influenza viruses. These include chicken, turkey, ducks, guinea fowl, domestic geese, quail, pheasant, partridge, mynah birds, passerines, psittacine, budgerigars, gulls, shorebirds, seabirds and emu (Easterday *et al.*, 1997; Webster and Kawaoka, 1988). Avian influenza A viruses produce an array of syndrome in poultry, ranging from asymptomatic to mild upper respiratory infections to loss of egg production to rapidly fatal systemic disease (Easterday *et al.*, 1997). Some infected birds show symptoms of avian influenza, while others do not. The types of presenting clinical signs depend on the species and age of the poultry, the strain of AI virus, and accompany bacterial infections (Webster and Kawaoka, 1988; Easterday *et al.*, 1997). Occasionally, the poultry will die without showing any clinical signs of illness (Campbell *et al.*, 1970; Alexander *et al.*, 1993).

In layer chickens, the ovary may be hemorrhagic. The general condition of the poultry and food intake were dramatically changed in all poultry studied. These findings are consistent with those of previous study (Jacob *et al.*, 2003) and may suggest that species adaption and maximal pathogenicity of avian influenza infection for their corresponding species of the poultry (Alexander *et al.*, 1978; Tashiro *et al.*, 1987).

The pathological anatomy lesions in the infected AI chicken (layer and backyard chickens) are quite similar.

Some of the gross lesions differences observed among studied poultry may reflect differences in species of the poultry. Swelling of the head and face, cyanosis of unfeathered skin (especially the combs and wattles), and swollen and petechial hemorrhages of the foot and muscles, especially breast and thigh muscles, abdominal fats and proventriculus were only observed in the chicken, but not in the quails. The quails had a severely decreased in the general condition and food intakes.

It was reported that systemic replication of avian influenza virus in chicken and turkey is largely defined by the presence of multiple basic amino acids at the hemagglutinin cleavage site (Senne *et al.*, 1996, Wood *et al.*, 1993; Klenk and Rott, 1988). Despite this molecular conformity among H5 and H7 high pathogenic avian viruses, considerable variation has been observed in the pathogenicity and transmissibility of these viruses in different avian species, even within the avian order Galliformes. For example, the A/turkey/Ontario/7732/66 (H5N9) influenza virus is moderately pathogenic for the chickens and quail, highly pathogenic in turkeys, and apathogenic in pheasants, pigeons, and ducks (Slemons and Easterday, 1972). Therefore, because of the differences in virulence avian influenza viruses demonstrate in domesticated avian species, it is important to consider possible ramifications of interspecies transmission of influenza viruses when different poultry species are commingled.

CONCLUSION

The highly pathogenic avian influenza is suspected with any flock where sudden deaths follow severe depression, in acceptance, and a drastic decline in egg production. The present of facial edema, swollen and cyanotic unfeathered skin, especially combs and wattles, and petechial hemorrhages on the internal membrane surfaces, foot and muscles, especially breast and thigh

muscles increases the likelihood that the disease is highly pathogenic avian influenza. Highly pathogenic avian influenza H5N1 infection is easily confused with primarily Newcastle disease because the disease clinical signs (torticollis and curled-toe paralysis) and postmortem lesions (petechial hemorrhages of the internal organs) are similar. However, in an area where AI is endemic, such as during an outbreak, sound presumptive diagnoses can be made by flock history, clinical signs, and gross lesions.

REFERENCES

- Alexander DJ, Allan WH, Parsons DG, Parsons G (1978) The pathogenicity of four avian influenza viruses for fowls, turkeys and ducks. *Res. Vet. Sci.* 24: 242-247.
- Alexander DJ, Lister SA, Johnson MJ, Randall CJ, Thomas PJ (1993). An outbreak of highly pathogenic avian influenza in turkeys in Great Britain in 1991. *Vet. Rec.* 132: 535-536.
- Anonymous (2002). Highly pathogenic avian influenza: A threat to U.S. poultry. United States Department of Agriculture. Animal and Plant Health Inspection Service. USA.
- Bosch FX, Garten W, Klenk HD, Rott R (1981). Proteolytic cleavage of influenza virus hemagglutinins: Primary structure of the connecting peptide between HA1 and HA2 determines proteolytic cleavability and pathogenicity of avian influenza viruses. *Virology* 113: 725-735.
- Campbell CH, Webster RG, Breese SSJ (1970). Fowl plaque virus from man. *J. Infect. Dis.* 122: 513-516.
- Easterday BC, Hinshaw VS, Halvorson DA (1997). Influenza. In: *Disease of poultry*. Tenth Ed. B.W. Calnek, H. John Barnes, Charles W. Beard and Larry R. McDougald. Iowa State University Press. Ames, Iowa, USA.
- Jacob JP, Butcher GD, Mather FB, Miles RD (2003). Avian influenza in poultry. IFAS Extension. University of Florida. Gainesville, 32611, Fl., USA.
- Kawaoka Y, Nestorowicz DJ, Alexander DJ, Webster RG (1987). Molecular analyses of the hemagglutinin genes of H5 influenza viruses origin of a virulent turkey strain. *Virology* 158: 218-227.
- Klenk HD, Rott R (1988). The molecular biology of influenza virus pathogenicity. *Adv. Virus Res.* 34: 247-281.
- Lamb RA, Krug RM (1996). Orthomyxoviridae: The viruses and their replication. In: Fields B.N., Knipe D.M. and Howley, P.M. (Eds). *Field's Virology*. Lippincott-Raven, Philadelphia, USA.
- Peiris JSM, Guan Y, Markwell D, Ghose P, Webster RG, Shortridge KF (2001). Cocirculation of avian H9N2 and contemporary "human" H3N2 influenza A viruses in pigs in Southeastern China: Potential for genetic reassortment? *J. Virol.* 20: 9679-9686.
- Senne DA, Panigrahy B, Kawaoka Y, Pearson JE, Suss J, Lipkind M, Kida H, Webster RG (1996). Survey of the hemagglutinin (HA) cleavage site sequence of H5 and H7 avian influenza viruses: Amino acid sequence at the HA cleavage site as a marker of pathogenicity potential. *Avian Dis.* 40: 425-437.
- Slemons RD, Easterday BC (1972). Host response differences among 5 avian species to an influenza virus-A/turkey/Ontaria/7732/66 (Hav5N?). *Bull. WHO* 47: 521-525.
- Tashiro M, Reinacher M, Rott R (1987). Aggravation of pathogenicity of an avian influenza virus by adaption to quails. *Arch. Virol.* 93: 81-95.
- Webster RG, Kawaoka Y (1988). Avian influenza. *Crit. Rev. Poult. Biol.* 1: 211-246.
- Wood GW, McCauley JW, Bashiruddin JB, Alexander DJ (1993). Deduced amino acid sequences at the hemagglutinin cleavage site of avian influenza A viruses of H5 and H7 subtypes. *Arch. Virol.* 130: 209-217.
- Wuryastuti H, Widyarini S, Yanuartono Adji D, Tjahyowati G. dan Wasito, R. (2005). Kajian perkembangan *avian influenza* (AI) pada unggas. Laporan. Direktorat Jenderal Produksi Peternakan, Jakarta.