

Full Length Research Paper

Agreement and Discrepancy between Optical Coherence Tomography and Fundal Fluorescein Angiography in Detection of Macular Edema

Mahgoub Saleem* and Mawahib Ibrahim, MD

Abstract

Associate Professor, Faculty of
Medicine, Al Neelain University
Khartoum 11111, P. O. Box 10139,
Sudan

*Correspondence Author's E-mail:
saleem4eyes@gmail.com

Macular edema (ME) is a common cause of a sudden or chronic decrease in visual acuity. It refers to accumulation of fluids within the retinal macular layers due to pathological disruption in the normal blood-retinal barrier (BRB). To determine the agreement and discrepancy between the Optical Coherence Tomography (OCT) and Fundus Fluorescein Angiography (FFA) in detection of Macular Edema (ME) of deferent causes. In a prospective, descriptive cross sectional study over a 6 month period at Makkah Eye Complex (MEC) Retina clinic, Diabetic Eye Clinic and Ophthalmic Investigation Department. Interpretation of OCTs and FFAs images was done for consecutive 252 eyes that had undergone FFA and OCT simultaneously to rule out ME. Of 252 eyes, 232 eyes (92.1%) had the finding of ME confirmed by both techniques. There were 8 eyes (3%) for which FFA showed dye leakage in the macular area and OCT showed normal foveal contour and no intraretinal edema. For 12 eyes in the study (5%), OCT showed intraretinal and subretinal fluid, which was not detected by FFA. Both FFA and OCT are highly sensitive techniques and correlate well in detection of ME. However, there is a small chance that when performed alone they might miss existing subtle ME.

Keyword: Blood-retinal barrier, Fundal Fluorescein Angiography, Optical Coherence Tomography Macular Edema, intraretinal fluid, subretinal fluid.

INTRODUCTION

ME is a relatively common condition (Telander DG et al.,2010) in which there is an abnormal fluid retention within the retinal macular layers resulting in an increase in the retinal thickness. ME may be of cytotoxic or vasogenic origin (Bernardes and Cunha-Vaz, 2012), both due to many intraocular and systemic insults (Tranos et al., 2004) which are implicated in BRB breakdown. ME is a leading cause of sudden or chronic visual loss (Maalej et al., 2012) in a variety of pathological conditions such as intraocular inflammation (Rotsos and Moschos, 2008),diabetic retinopathy (Gonzalez, 2007) age-related macular degeneration (Rotsos and Moschos, 2008), retinal vein occlusion (Turralde et al., 2006), uveitis

(Kozak,et al., 2008), Retinitis pigmentosa (Scorolli et al., 2007), and hypertension (Basic and Clinical Science Course, 2010-2011), toxemia of pregnancy (Gitter et al., 1968), collagen vascular disease (Agrawel, 2014), and post cataract surgery (Telander DG et al.,2010; A.12 Henderson et al., 2007).

Objective assessment of the presence and measurements of ME can be obtained accurately by FFA and OCT (Maalej et al., 2012; Maalej et al., 2012; Kulkarni and Michael, 2012). FFA is an essential invasive sensitive imaging technique of identifying the presence of ME, but relatively of little information regarding its anatomical distribution and the severity of the leak over time

Table 1. Distribution of subjects according to diagnoses

Diagnoses	No.	Frequency
DR	219	86.9 %
ARMD	12	4.8 %
CRVO	7	2.8 %
Hypertensive retinopathy	5	2.0 %
CSCR	4	1.6 %
BRVO	2	0.8 %
Uveitis	2	0.8 %
DR+ BRVO	1	0.4 %
Total	252	100.0 %

Table 2. Age distribution of the study population

Age group in years	No.	Frequency
30-40 years	8	3.2 %
40-50 years	47	18.7 %
50-60 years	105	41.7 %
60-70 years	78	31.0 %
70-80 years	14	5.6 %
Total	252	100.0 %

Table 3. FFA late phase

Late phase leak	No. of eyes	Percentage %
Late phase leak positive	240	95.2% (95%)
Late phase leak negative	12	4.8% (5%)
Total	252	100.0%

(Ober et al., 2014). OCT is noninvasive imaging technique that provides a useful tool of diagnosing ME. Moreover gives accurate measurements of the retinal thickness and exact anatomical distribution and the severity of the leak over time. It also demonstrates the character of vitreoretinal interface regarding vitreomacular traction which plays a role in the formation of ME (Ober et al., 2014; Optical Coherence Tomography, 2013).

MATERIALS AND METHODS

Results of a consecutive two hundred fifty-two good-quality OCT and FFA for patients referred to the Department of Ophthalmic Investigations by retina specialists at MEC, with a diagnosis or suspected ME due to deferent causes. All selected patients had simultaneously undergone both FFA and OCT, over a 6-month period (September^{1st} 2012 to March^{1st} 2013) was included in this study. Clinical and personal information were obtained by direct patients and charts review. Exclusion criteria were determined by the poor quality images and uncooperative patient's reactions.

Ethical approval was obtained from Makkah Research Center (MRC). Informed consent was obtained from

patients and they were reassured that their data will be kept in confidentiality.

RESULTS

Simultaneous, good-quality 252 FFA and OCT results of 163 patients (89 bilateral) with ME of different etiological causes (Table 1) were computed. The mean age of the study group was 49 ± 12.1 years (32 to 78years) (Table 2), 90 (55.21%) males and 73(44.79%) females.

Detection of ME by FFA shown in the "late FFA phase" macular dye leakage in 240 eyes (95%) (Table 3), and failed to detect the edema in 12 patients (5%). While OCT detected ME in the form of intraretinal edema in 244 (97%) eyes (Table 4), beside other useful features that indicate the presence of ME; as it showed disrupted central foveal contour in 72.6% of cases (Table 5), intraretinal cysts in 108 eyes (Table 6), subretinal fluid (SRF) in 31eyes (Table 7) and vitreomacular traction (VMT) in 26 eyes (Table 8). On the other hand the OCT failed to detect ME in 8 eyes (3%). All useful features were missed by FFA. It was found that most of the cases of discrepancy were found in diabetic ME, Aged related macular degeneration (ARMD) and central serous chorioretinopathy (CSCR).

Table 4. OCT intraretinal edema

Central foveal contour	No.	Percentage %
Regular	244	96.8% (97%)
Disrupted	8	3.2 %
Total	252	100.0 %

Table 5. OCT: Central foveal contour

Central foveal contour	No.	Percentage %
Regular	69	27.4 %
Disrupted	183	72.6 %
Total	252	100.0 %

Table 6. OCT: intraretinal cysts

Intraretinal cysts	No.	Percentage %
Yes	108	42.9%
No	144	57.1 %
Total	252	100.0 %

Table 7. OCT: Subretinal fluid

Subretinal fluid	No.	Percentage %
Yes	31	12.3%
No	221	87.7 %
Total	252	100.0 %

Table 8. OCT: Vitreomacular Traction

VMT	No.	Percentage %
Yes	26	10.3%
No	226	89.7%
Total	252	100.0 %

232 eyes (92.1%) had confirmation of the diagnosis of ME by both techniques. Sensitivity of OCT for ME was 97% while that of FFA was 95%. Cross tabulation was done to determine the agreement between FFA and OCT (Table 10), κ for agreement reliability was 0.95.

There were 8 eyes (3%) for which FFA showed dye leakage in the macular area and OCT showed normal foveal contour and normal thickness of the adjacent retina. For 12 eyes in the study (5%), OCT showed intraretinal as well as subretinal fluid, which was missed by FFA.

DISCUSSION

ME in its various forms can be considered as a common factor for the painless (Qazi, 2012) decrease of central vision in a wide variety of intraocular and systemic pathological conditions (Cho and Madu, 2009). Its

accurate clinical assessment may be subjective and variable, so always should be correlated with the degree of loss of visual acuity (Kozak et al., 2008). Apart from an expert stereoscopic fundus biomicroscopy which is relatively insensitive for ME detection, another more precise and reliable diagnostic approaches to evaluate ME is done by OCT and FFA (Maalej et al., 2012; Maalej et al., 2012; Kulkarni and Michael, 2012; Qazi, 2012).

In the current study the sensitivity of OCT (97%) was slightly higher than that of FFA (95%). However, the agreement between the two was reasonably good, showing κ (*The Kappa Statistic; which is most often used to measure agreement between a binary variable* (Sim and Wright, 2005)) for agreement up to "0.95". This in contrary with the low result of Augusto P J and his colleagues at São Paulo, Brazil; who found κ to be only "0.61"; which represents a fair agreement among the OCT and FFA groups However this low Augusto's κ value can be explained by their small sample size

Table 9. Detection of ME by FFA and OCT

Detection of ME	By FFA		By OCT	
	No.	%	No.	%
Positive for ME	240	95%	244	97%
Negative for ME	12	5%	8	3%
Total	252	100%	252	100%

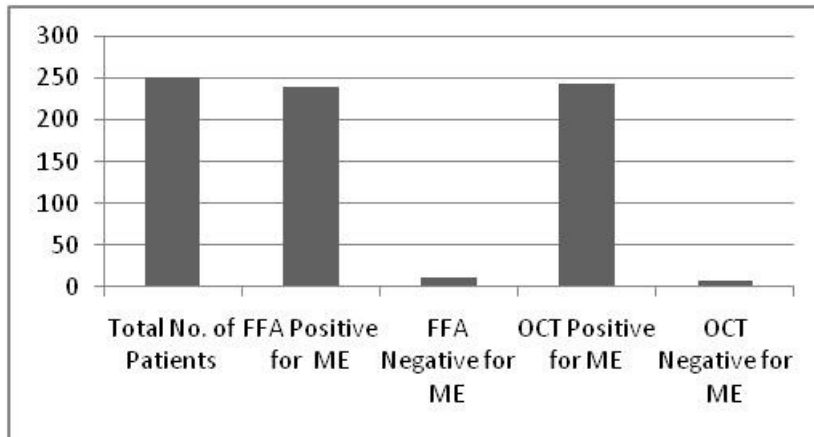


Figure 1. Detection of ME by FFA and OCT

Table 10. FFA *OCT Cross tabulation

Table (11) FFA * OCT Cross tabulation			OCT		Total	Sensitivity	CI	
			Negative	Positive			Lower level	Upper level
FFA	Positive	Count % within FFA	8 3.3%	232 96.7%	240 100.0%	0.95	0.91	0.97
	Negative	Count % within FFA	0 0.0%	12 100.0%	12 100.0%			
Total		Count % within FFA	8 3.2%	244 96.8%	252 100.0%			

(25eyes) and the ME type, as they examined only Cystoid ME after cataract surgery (Augusto et al., 2012).

Igor Kozak and his team at Shiley Eye Center of University of California in San Diego (Kozak et al., 2008), who examined ME of various etiologies in a large sample size (1,272 eyes); found that the sensitivity of OCT for ME (96.1%) was slightly lower than that of FFA for ME (98.7%), however their κ value for agreement between OCT and FFA (0.90) represents very good agreement among the two grading groups (Kozak et al., 2008). In the above Igor Kozak's results the supremacy of FFA over OCT was due to the use of time domain stratus OCT model (TD-OCT) which is less sensitive than the spectral domain OCT(SD-OCT) (Hunter et al., 2013) used in our current study.

The discrepancy in the findings between OCT and FFA in detection of ME in the current study was demonstrated well by the positive late phase FFA macular dye leakage in 8 eyes (3%) in which OCT detected normal thickness and contour. Also in the 12 eyes (5%) where OCT showed intraretinal as well as subretinal fluid, which was missed by FFA (Table 9). (Figure 1)

The current results can be comparable in one side with the 3.86% that was detected by FFA and missed by OCT in San Diego study, and incomparable in another side with their 1.17% that were detected by OCT and missed by FFA in the same study (Augusto et al., 2012).

The few missed cases by OCT in this study might have been the result of the subtle diffusion of dye in FFA

that is not associated with retinal tissue changes especially after laser treatment. However Soliman et al (Augusto et al., 2012) found that early morphologic changes in diabetic ME may be seen better with FFA than with OCT. In our study FFA missed intraretinal fluid detected by OCT especially in cases associated with VMT; also subretinal fluid was missed by FFA in some cases. The later was a common observation in many previous studies (Kozak et al., 2008; Jittpoonkuson et al., 2010; Chhablani and Sudhalkar, 2014).

CONCLUSION

OCT and FFA are available highly sensitive imaging techniques for objective assessment, measurements and follow up of ME cases. However, there is a small chance that when performed alone they might miss existing subtle ME. There is good agreement between the two techniques never the less; there're some cases of discrepancy where both can occasionally miss ME. So advisable to be performed simultaneously to rule out the severity and type of ME.

ACKNOWLEDGMENTS

Dr Ahmed Raslan, Head of Department of Ophthalmic Investigations at MEC, Khartoum, Sudan.

Disclaimer

The authors hold no financial or conflict of interest.

REFERENCES

- A12. Henderson BA, Kim JY, Ament CS, Ferrufino-Ponce ZK, Grabowska A, Cremers SL (2007). Clinical pseudophakic cystoid macular edema. Risk factors for development and duration after treatment. *J Cataract Refract Surg.* Sep; 33(9):1550-8. (Medline)
- Agrawal A (2014). Gass' Atlas of Macular Diseases; Fifth Edition; Elsevier Inc.; Chapter 7 : Macular Dysfunction Caused by Vitreous and Vitreoretinal Interface Abnormalities; Retinal Arteriolar Obstruction Caused by Systemic Hypertension and Collagen Vascular Disease.
- Augusto P J, Mitne S, Rodrigues A P, Rodrigues APS, GuiaT, Bordon A, de Moraes NSB, Eid Farah ME, Pedro Paulo Bonomo PP (2012). Agreement between optical coherence tomography and fundus fluorescein angiography in post-cataract surgery cystoid macular edema. *Arq Bras Oftalmol* 2003;66(771);4 (PubMed), accessed on August.
- Basic and Clinical Science Course (2010-2011). Section 12: Retina and Vitreous; American Academy of Ophthalmology.
- Bernardes R, Cunha-Vaz J (2012). Optical Coherence Tomography: A Clinical and Technical Update, XV,255p.124 illus.,86 illus. ISBN:978-3-642-27409-1; Springer.
- Chhablani J, Sudhalkar A (2014). Fluorescein Angiography and Optical Coherence Tomography Correlation in Various Retinal Diseases. *Retin Today*; February
- Cho H and Madu A (2009). Etiology and treatment of the inflammatory causes of cystoid macular edema *J Inflamm Res.*; 2: 37–43; PMID: PMC3218725.
- Gitter KA, Houser BP, Sarin LK, Justice J Jr (1968). Toxemia of Pregnancy An Angiographic Interpretation of Fundus Changes. *Arch Ophthalmol.*;80(4):449-454. doi:10.1001/archoph.1968.00980050451008.
- Gonzalez VH (2007). Laser and Pharmacologic Therapies in the Treatment of Diabetic Macular Edema. *Retinal Physician*, Issue: January.
- Hunter A, Chin EK, Telander DG (2013). Macular edema in the era of spectral-domain optical coherence tomography. *Clin Ophthalmol.*;7:2085-2089. Epub 2013 Oct 18. (PubMed)
- Kozak I, Victoria L, Morrison VL, Thomas M, Clark TM, Bartsch DU, Lee BR, Falkenstein I, Tammewar AT, Mojana F, Md, Freeman WR (2008). Discrepancy Between Fluorescein Angiography And Optical Coherence Tomography In Detection Of Macular Disease. *Retina.* Apr; 28(4): 538–544. doi: 10.1097/ IAE. 0b 013e 318167270b; PMID: PMC2666014
- Iturralde D, Spaide RF, CatherineB, Jay MK, Lawrence AY, Yale FI, John S, Jason SS, Bailey FK, Michael C, Howard FF (2006). Intravitreal Bevacizumab (Avastin) Treatment of Macular Edema in Central Retinal Vein Occlusion: A Short-term Study. *Retina: March - Volume 26 - Issue 3 - pp 279-284*
- Jittpoonkuson T, PMT Garcia, RB Rosen (2010). Correlation Between Fluorescein Angiography and Spectral-domain Optical Coherence Tomography in the Diagnosis of Cystoid Macular Edema, the British Journal of Ophthalmology ;94(9):1197-1200, Medscape Education , [PubMed], accessed on January 2013.
- Kozak I, Morrison VL, Clark TM, Bartsch DU, Lee BR, Falkenstein I, Tammewar AM, Mojana F, Freeman WR (2008). Discrepancy Between Fluorescein Angiography And Optical Coherence Tomography in Detection of Macular Disease. *Retina.* April; 28(4): 538–544. doi: 10.1097/IAE.0b013e318167270b.
- Kulkarni AD and Michael S (2012). Diabetic Macular Edema: Therapeutic Options. *Diabetes Ther.* December; 3(1): 2. Published online 2012 March 6. doi: 10.1007/s13300-012-0002-y.PMID: PMC3508119.
- Maalej A, Cheima W, Asma K, Riadh R, Salem G (2012). Optical Coherence Tomography for Diabetic Macular Edema: Early Diagnosis, Classification and Quantitative Assessment. *Maalej et al., J Clinic Experiment Ophthalmol*, S: 2.
- Maalej A, Cheima W, Asma K, Riadh R, Salem G (2012). Optical Coherence Tomography for Diabetic Macular Edema: Early Diagnosis, Classification and Quantitative Assessment. *J Clinic Experiment Ophthalmol* S2:004. doi:10.4172/2155-9570.S2-004.
- Ober MD, Klais CM, Cunningham ET Jr (2014). Management Options for Macular Edema. *Review of Ophthalmology*, Dec 30, 2005, accessed on Feb.
- Optical Coherence Tomography (2013). Contributed by Marc. J .S D, <http://eyewiki.aao.org> , accessed on March.
- Qazi HA (2012). Protocol: Effect of intravitreal bevacizumab (avastin) in the treatment of macular edema: A systematic review of randomized controlled trials *J Res Med Sci.* December; 17(12): 1180–1187. PMID: PMC3703172.
- Rotsos TG, Moschos MM (2008). Cystoid macular edema *Clin Ophthalmol.* Dec 2008; 2(4): 919–930. Published online Dec. PMID: PMC2699812
- Rotsos TG, Moschos MM (2008). Cystoid macular edema. *Clin Ophthalmol.* December; 2(4): 919–930. PMID: PMC2699812.
- Scorolli L, Morara M, Meduri A, Reggiani LB, Ferreri G, Scalinci SZ, Meduri RA (2007). Treatment of Cystoid Macular Edema in Retinitis Pigmentosa With Intravitreal Triamcinolone. *Arch Ophthalmol.*; 125(6):759-764. doi:10.1001/archoph.125.6.759
- Sim J, Wright CC (2005). The Kappa Statistic in Reliability Studies: Use, Interpretation, and Sample Size Requirements. *Physical Therapy* March vol. 85 no. 3 257-268.

014 Merit Res. J. Microbiol. Biol. Sci.

Telander DG, Cessna CT, Phillpotts BA, Talavera F, Charles S, Brown LL, Sir Roy H (2010). Macular Edema, Pseudophakic (Irvine-Gass), eMedicine; Medscape, Apr.

Tranos PG, Wickremasinghe SS, Stangos NT, Topouzis F, Tsinopoulos I, Pavesio CE (2004). Macular edema. Surv Ophthalmol. Sep-Oct;49(5):470-90. PMID:15325193. (PubMed).